Intestinal-type sinonasal adenocarcinoma

Lester D.R. Thompson, MD

Adenocarcinomas of the sinonasal tract can originate in the respiratory epithelium or the underlying mucoserous glands. Most (60%) arise from the mucoserous glands. These tumors are divided into two categories: salivary-gland–type and nonsalivary-gland–type adenocarcinomas (table). The latter are subdivided into two major categories: intestinal-type adenocarcinomas (ITACs) and nonintestinal-type adenocarcinomas.

Table. Classification of sinonasal adenocarcinomas

Type	Subtype	Description
Salivary-gland–type adenocarcinoma	N/A	Mucoepidermoid carcinoma, adenoid cystic carcinoma, acinic cell carcinoma, epithelial-myoepithelial carcinoma, clear-cell carcinoma, and polymorphous low-grade adenocarcinoma, among others
Intestinal-type adenocarcinoma	Papillary	Papillary tubular cylinder-cell type I
	Colonic	Papillary tubular cylinder-cell type II
	Solid	Papillary tubular cylinder-cell type III
	Mucinous	Alveolar goblet type and signet-ring type
	Mixed	Transitional
Nonintestinal-type adenocarcinoma	Low grade	
	High grade	

Nonintestinal-type adenocarcinomas are subclassified as low- and high-grade tumors. They are slightly more common in men than women. These tumors occur in a wide range of ages; low-grade tumors tend to occur in patients about a decade earlier than do high-grade tumors (mean ages at diagnosis: 54 and 63 yr, respectively). The ethmoid and maxillary sinuses tend to be affected more often than other sites.

ITACs are a heterogeneous group of tumors, and they are further classified into a variety of subtypes (papillary, colonic, solid, mucinous, and mixed) that are associated with clinically significant differences in outcomes. ITACs have a strong male predominance (~90% of cases), and they tend to affect older patients (mean: 60 yr). There is a well-known occupational risk after prolonged exposure (frequently decades), particularly among woodworkers and leather workers. Although the actual carcinogenic substance is unknown, it is believed to be particulate in nature, as spouses of these workers are also at increased risk. Moreover, the lower and middle turbinates are the most commonly affected areas, which suggests an initial entry point for inspired material. The most common symptoms of ITACs are unilateral obstruction, rhinorrhea, and epistaxis. These tumors tend to be identified at an early stage, thanks to a heightened awareness and industrial screening programs in associated occupations.

ITACs are made up of absorptive cells and goblet cells that form glands, nests, and abundant mucin. The degree of differentiation varies. Some are extremely well differentiated, having the appearance of a colonic tubular adenoma or villous adenoma. They have nuclear stratification and mild nuclear atypia (figure 1). Some tumors contain small intestinal-type cells, such as Paneth cells and enterochromaffin cells. Occurring at the base of the glands are a few layers of smooth-

From the Department of Pathology, Woodland Hills Medical Center, Southern California Permanente Medical Group, Woodland Hills, Calif.

muscle cells that resemble muscularis mucosa. Other tumors resemble moderately differentiated colonic adenocarcinomas with confluent glands, nuclear pleomorphism, prominent nucleoli, and increased mitotic activity. Some tumor cells produce abundant mucinous material (figure 2). Necrosis is common. Papillary and solid patterns are also recognized. In all cases, patients should be examined for evidence of intestinal tumor before the neoplasm is accepted as a primary lesion of the upper respiratory tract.

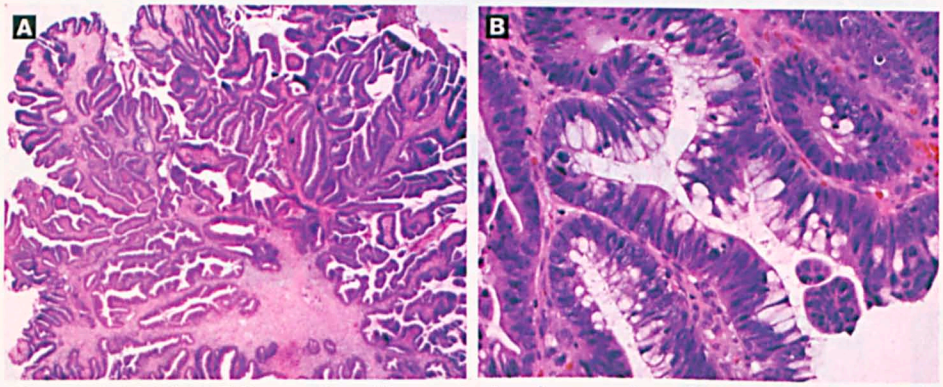

Figure 1. ***A:*** *Multiple villiform and papillary projections from a major stalk are seen in this papillary-type ITAC. The resemblance to a colonic tubular adenoma is easy to recognize.* ***B:*** *At higher power, the papillary projections demonstrate nuclear stratification with goblet cells. Mitotic figures are easily identified. These features are almost identical to those of a colonic adenoma.*

ITACs show keratin, EMA, B72.3, CK7, CK20, and CDX-2 immunoreactivity. CK20 and CDX-2 are both markers used to confirm intestinal (colonic) differentiation in colon primaries, and they are coexpressed in these sinonasal tract tumors (figure 3).

Schneiderian papillomas (the oncocytic variant in particular), with their complex back-to-back confluent glands and papillary architecture, may be overdiagnosed as low-grade adenocarcinomas, but the cells are cytologically benign.

Among patients with nonsalivary-gland–type adenocarcinomas, histologic grade affects outcome. Well-differentiated tumors with predominantly papillary and tubular structures are associated with a better prognosis (5-year survival: 80%) than their poorly differentiated counterparts (5-year survival: 40%). Patients whose disease is associated with occupational exposure have a better outcome than those with sporadic cases, perhaps because the former are generally under surveillance. Recurrence develops in approximately 50% of patients and distant metastasis in about 15%. Overall survival is about 40%, with death occurring in about 3 years. Treatment is radical surgical resection and postoperative radiotherapy.

Suggested reading

Barnes L. Intestinal-type adenocarcinoma of the nasal cavity and paranasal sinuses. Am J Surg Pathol 1986;10(3):192-202.

Kleinsasser O, Schroeder HG. Adenocarcinomas of the inner nose after exposure to wood dust. Morphological findings and relationships between histopathology and clinical behavior in 79 cases. Arch Otorhinolaryngol 1988;245(1):1-15.

Llorente JL, Pérez-Escuredo J, Alvarez-Marcos C, et al. Genetic and clinical aspects of wood dust related intestinal-type sinonasal adenocarcinoma: A review. Eur Arch Otorhinolaryngol 2009;266(1):1-7.

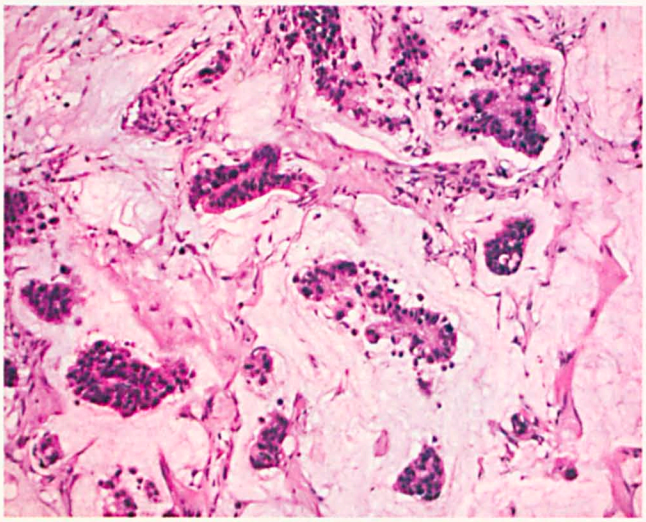

Figure 2. Lakes and pools of mucinous material surround the neoplastic glandular elements in this mucinous ITAC. There is cytologic atypia.

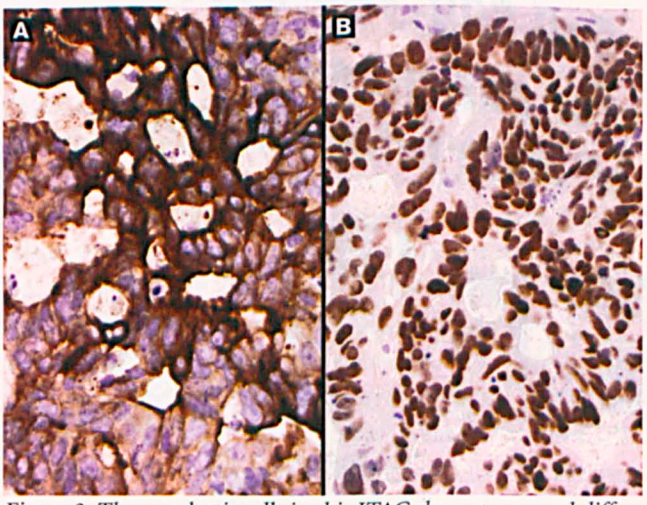

*Figure 3. The neoplastic cells in this ITAC show strong and diffuse immunoreactivity with CK20 (**A**) and strong nuclear reactivity with CDX-2 (**B**). Both of these are considered colon tumor markers, confirming the intestinal-type phenotype.*